

# UTERINE FIBROID CASE



## Presenting Complaint

32 year old female with menorrhagia and pelvic pain.

## Imaging

### *Pelvic Ultrasound*

Multiple myometrial fibroids.

### *Pelvic MRI*

Confirms myometrial fibroids with largest fibroid measures 7.5cm and demonstrates uterine artery anatomy.

## Management

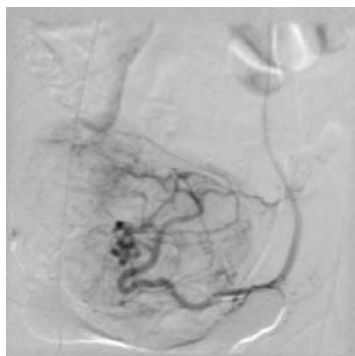
Patient undergoes uterine fibroid embolisation using calibrated embospheres (gelatin based liquid embolic agent) to reduce blood flow to the fibroids. Discharged home next day.

## Intra and Post Procedure Care

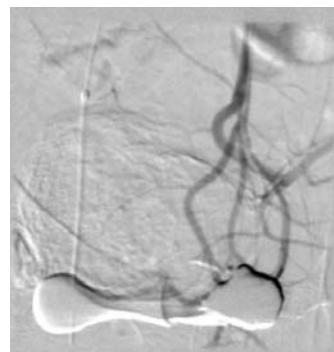
Patient controlled anaesthesia (PCA pump) for 12 hours then oral Analgesia (Paracetamol and Voltaren for 3-5 days) .

## Follow-up

6 month MRI— reduction in size of fibroid (3cm) and normal menstruation.



Pre-treatment



Post-treatment