

ANGIOPLASTY CASE



Angioplasty

Re-opens blocked or narrowed blood vessels by inserting a balloon into the vessel and inflating it.

Indications for Angioplasty

- Severe Claudication (< 100m)
- Rest Pain
- Ischemic Ulceration

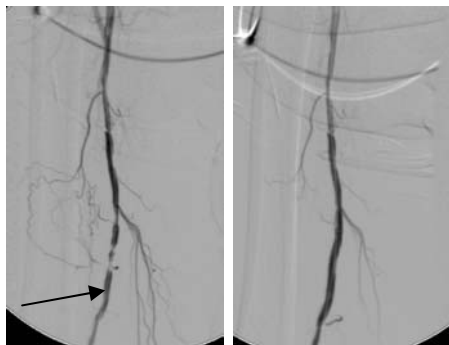
Case Study – Angioplasty Right Superficial Femoral Artery

Symptoms – 65 year old male smoker with type 2 diabetes with right sided intermittent claudication (50m) and unable to play golf.

Diagnosis – Duplex ultrasound shows 80% stenosis of the right mid Superficial femoral artery.

Treatment – Percutaneous balloon angioplasty (PTA) was performed. Patient discharged home next day.

Follow Up – Symptom free at 1 year and playing golf.



Pre-treatment

Post-treatment